

Human Round Window: Morphometry and Topographical Anatomy and their Effect on Cochlear Implantation.

Ahmed Seliet¹, Ashraf El Hamshary¹, Ahmed Elrefai², Ali Mohamed³ and Sara Gabal⁴

1 Professor of Otorhinolaryngeology Benha University 2 Lecturer of Otorhinolaryngeology Benha University 3 Lecturer of Anatomy and Embryology Benha University 4 Demonstrator of Otorhinolaryngeology Benha University

Abstract

Renewal interest of round window (RW) approaches necessitates further acquaintance of its complex anatomy and its variations. The aim of this work is to study the anatomical characteristics of human RW and the importance of variations in this anatomy to the process of cochlear implantation (CI). Twenty human temporal bones were obtained from cadavers and prepared in a formalin stain. Microdissection was done in 2 phases, phase 1 through facial recess approach and phase 2 external auditory canal approach after dissection of the bone in the area of round and oval window (OW), shape, height and width of the RW were noted. Its distances from OW was measured. Oval (60%), round (25%), triangular (15%) shapes of RW were observed. The average height and width of the RW were 1.91 ± 0.78 mm and 1.37 ± 0.43 mm, respectively. There was a statistically significant correlation ($r = 0.95$, $P < 0.001$) between the height and width of RW. The distances between the RW and the OW was in the range of 1 – 3.5 mm. There were no statistically significant differences with regard to gender, or side. Electrode insertion could be challenging in cases where the height and width of the RW are < 1 mm. This information could be useful for selecting cochlear implant electrodes in order to avoid potential risks to vital neurovascular structures during implant surgery.

Key words: human round window; anatomical variations; Cochleostomy; cochlear implantation.

Introduction

With the advent of new electrode designs and greater emphasis on preservation of residual hearing, there has been renewed interest in use of the round window as a portal for electrode insertion.^{1, 2}

Successful hearing preservation has been reported using the RW electrode insertion.^{3, 4} The RW membrane serves as a consistent landmark during CI surgery. Its continuity with the scala tympani ensures electrode insertion into this compartment while theoretically avoiding damage to the basilar membrane.⁵ Other benefits of RW insertion include minimizing acoustic trauma from drilling on the otic bone when creating a “traditional” cochleostomy that can exceed 130 dB^{6, 7}, minimizing loss of perilymph and entry of bone dust into the scala tympani, and reducing the iatrogenic damage and reactive inflammation that results from the use of a micro-drill when creating the cochleostomy.^{8, 9} Lastly, postoperative vertigo and loss of vestibular function may also be minimized with the RW approach over the traditional cochleostomy approach.¹⁰ It may also be possible to seal the tissues immediately around the electrode more effectively, thereby encouraging faster healing and decreasing the risk of inner ear infection associated with implantation⁶.

In addition, more basally located neuronal elements would potentially become available for stimulation with round window insertion because, by that approach, an electrode enters the cochlea in a more basal position than when using a conventional promontory cochleostomy.² In a temporal bone dissection study, *Paprocki et al., (2004)* found that round window insertion increases the length of osseous spiral lamina available for stimulation by approximately 2 mm relative to cochleostomy insertion.

Correct placement of the electrode array depends primarily on the surgeon’s intraoperative assessment of the RW in both approaches.^{12, 13} Imperfect electrode placement is a common cause of device failure leading to a devastating outcome for a patient anticipating hearing restoration.^{14, 15} A high incidence (33%) of anatomical variation in the RW has been documented in the literature¹⁶. Knowledge of variations in

the morphometry and topographical anatomy of RW is therefore important in surgical settings.¹⁷

The present work aims at studying the surgical anatomy of the round window as regard to its morphology, morphometry and its relation to oval window that may affect successful electrode insertion.

Materials and Methods

Thirty human wet cadaveric temporal bones were selected for the study from an autopsy materials of Anatomy and Embryology department Benha University. Ten bones were excluded because of traumatic damage of petrous temporal bone during anatomical preparation for cranial cavity contents. Thus, the anatomy was studied on twenty specimens only. This study was approved by the university Research Ethics Committee. Twenty cadaveric human temporal bones specimens (11 from the left side and 9 from right side; 13 male and 7 female) without any signs of ear pathology were fixed in 10% formalin and then were microscopically dissected in 2 phases:

- 1st phase (Facial recess approach): The temporal bones were opened using a posterior tympanotomy as it would be appropriate for cochlear implant surgery and to assess round window membrane visibility via the facial recess using an angle of view that provided maximum visibility of the round window niche.
- 2nd phase (External auditory canal approach): After the tympanic membrane and ear ossicles were removed, the RW and OW areas on the medial wall of tympanic cavity were exposed. The shape of the RW and its relation to OW were observed.

Measurement Procedure

The dissected bones were photographed using a standard operating room microscope equipped with a video camera system. The resulting images were imported to a computer. Dimensions were assessed and data were collected in an Excel-file. Each RW was graphically delineated and measurements were performed using NIH Image software, a public-domain image analysis program available <http://rsb.info.nih.gov/nih-image/>, for assessment of the proper RW contour and to determine the following parameters:

1. Shape of RW.
2. Maximum height of RW (RW_h).
3. Maximum width of RW (RW_w).
4. Distance between RW and oval window was measured from the anterior margin of round window to the anterior margin of oval window (RW-OW).

Statistical Analysis

The data were analyzed using the MS Office 2007 Excel spreadsheet (Microsoft Corp., Redmond, WA) and the program SPSS 20.0 (SPSS Inc., Chicago, IL). Mean, standard deviation (SD), and range of each parameter were computed. For pairwise comparison of group means between the two sexes and two sides, an unpaired t-test was used. Multiple regression was used in conjunction with Pearson's correlation analysis to ascertain the association of various distances from the RW with its height and width. The correlation of different parameters with age was also calculated using Pearson's correlation coefficient. A value of $P < 0.05$ was taken as statistically significant.

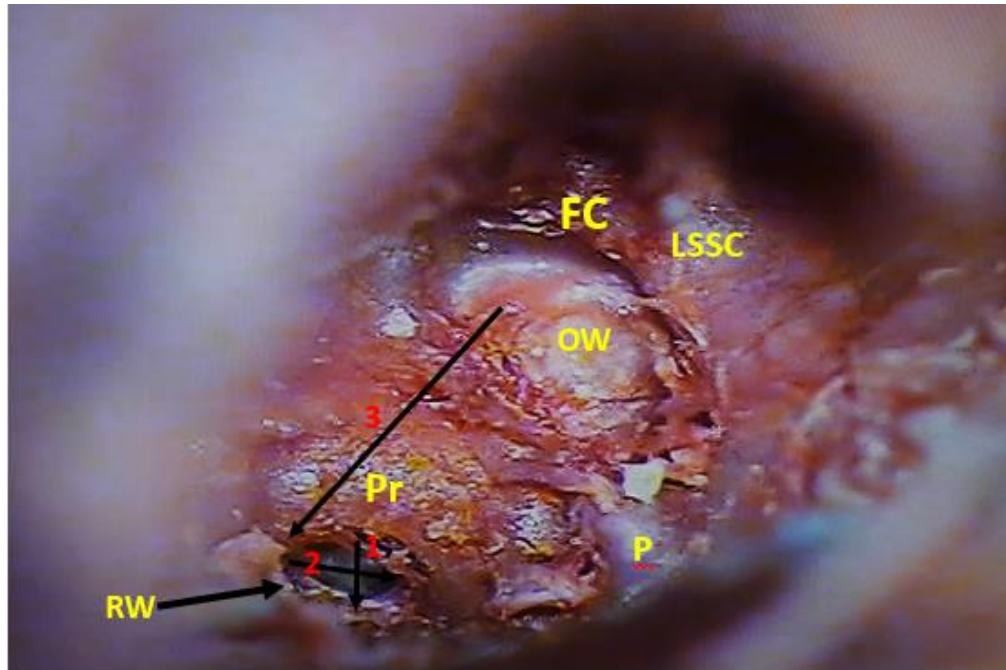


Fig. 1. Dissected left temporal bone showing measurement of different parameters of RW and its topography with adjacent structures on medial wall of tympanic cavity. RW, round window; OW, oval window occupied by stapes footplate; FC, facial canal; Pr, promontory; P, pyramid; LSSC, lateral semicircular canal.

1. Maximum height of round window (RW_h)
2. Maximum width of round window (RW_w)
3. Distance between round window and oval window (RW-OW) from anterior margin of RW to anterior margin of OW.

Results

Shape and Size of Round Window

The RW exhibited different shapes: oval (60%), round (25%), triangular (15%), (Fig. 2). Its average height and width were 1.91 ± 0.78 mm and 1.37 ± 0.43 mm, respectively (Table 1). The height ranged between 1 and 2 mm in 55% cases, and it was <1 mm in 10% cases. The width ranged between 1 and 2 mm in most specimens (75%) and was <1 mm in 25% (Fig. 3). There was a statistically significant correlation ($r = 0.92$, $P < 0.01$) between the height and width.

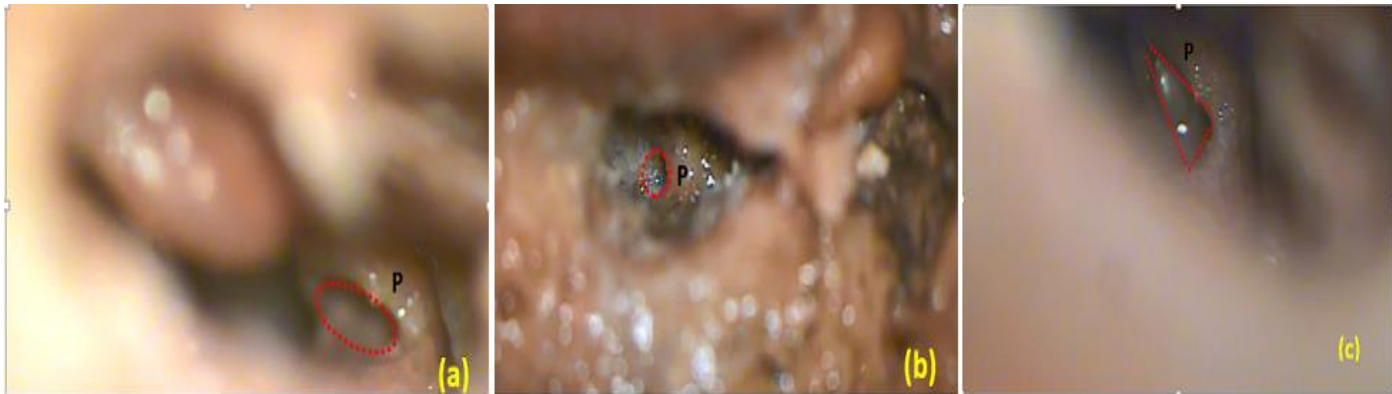

Fig. 2. Posterior tympanotomy view of round window revealing different shapes of RW: (a) Oval, (b) Round, (c) Triangular. P, promontory.

Relationship of RW with OW

The RW-OW distance was 2.09 ± 0.69 mm (Table 1). In most cases (55%), this distance was in the range of 2–3mm; while in 45% it was < 2 mm (Table 2).

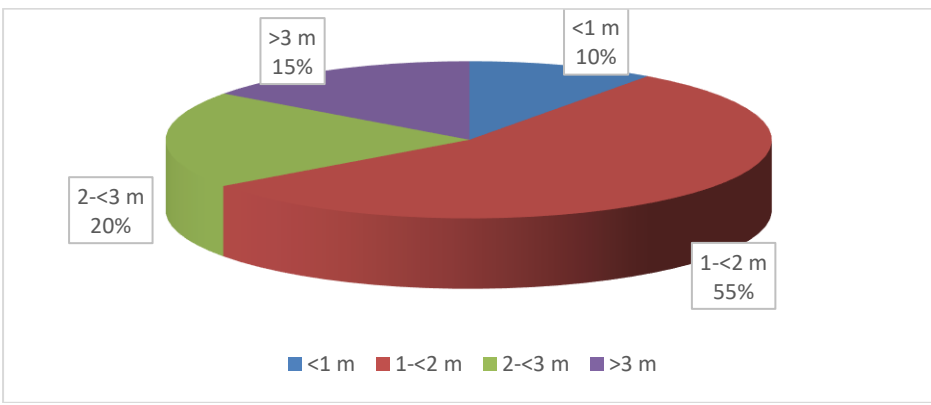
TABLE 1. Dimensions of RW and Distance of Round Window from oval window (n = 20)

PARAMETER	MEAN \pm SD	RANGE
RWH	1.91 ± 0.78	0.9 – 3.55
RWW	1.37 ± 0.43	0.65 – 2
RW-OW	2.09 ± 0.69	1 – 3.5

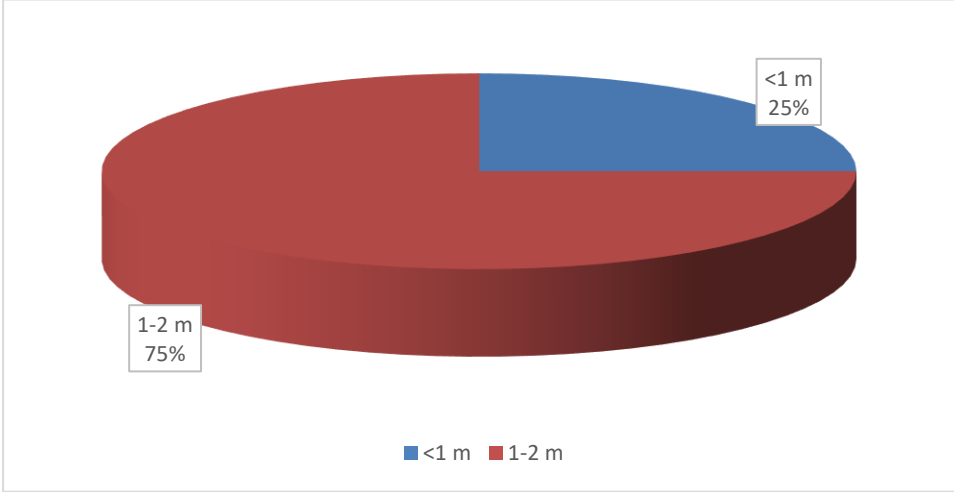
n, number of specimens; SD, standard deviation. Maximum height of round window (RWh), maximum width of round window (RWw), distance between round window and oval window (RW-OW).

Fig. 3. Pie chart depicting the frequency of height and width of round window (n =20).

Height of RW



Width of RW



In this study, there were no statistically significant differences between sexes or sides in any of the parameters. Multiple regression indicated significant correlations between RW width and height with RW-OW ($r = 0.96, P < 0.001$).

DISCUSSION

Cochlear implants (CIs) have been the treatment of choice for bilaterally hearing-impaired patients. Recent advances in CI electrode design have focused on placement of the electrode in a perimodiolar position, close to the spiral ganglion cells in Rosenthal's canal. Simultaneously, patient selection for CI surgery has changed over recent years as a result of improved speech perception benefits for CI users, so that patients with significant residual acoustic hearing are now potential candidates for cochlear implantation.¹⁸

Therefore, there is a renewed interest in using the residual acoustic hearing. The combined electrical and acoustic stimulation of the hearing impaired cochlea uses the still functional apical hair cells to perceive low-frequency sounds amplified by a hearing aid, while the high-frequency sounds are delivered electrically via a CI electrode. The human ear is able to integrate both acoustic and electrically processed speech information.¹⁹⁻²¹

Shape of RW

Variations in the shape of the RW can make it challenging to insert the electrode. The RW shapes in our collection were oval (60%), round (25%) and triangular (15%), as shown in Figure 2. Our results were in accordance with *Singla et al. (2014)* who found that the RW exhibited different shapes; oval (50%), round (20%) and triangular (12%), in addition to another three less common forms; comma- (10%), quadrangular- (6%), and pear- (2%) shaped ones.

In another study conducted by *Atturo et al. (2014a)* an archival collection of human microdissected temporal bones was analysed and photographed from the labyrinthine aspect. Human RW was seldom round but ovoid or orthogonal, skewed, and nonplanar (saddlelike).

Bonaldi et al. (1997) reported in a study conducted on 102 temporal bones that the RW was predominantly triangular appearance. Although the circular shape was sometimes present with a variable size, and in others, the window was oval. Sometimes half a moon or bean shapes were also observed.

Size of RW

As shown in Table 3, some previous authors have measured the diameter or half diameter of the RW (*Takahashi et al., 1989 ; Erixon et al. 2009*) and others have measured its length or *width* (*Singla et al. 2015; SU et al. 1982; Cohen et al. 2005*). Because the RW shape is variable, we preferred to measure its maximum height and width. In our study the average height of RW was found to be 1.91 ± 0.78 mm, and the average width of RW was also found to be 1.37 ± 0.43 mm.

Singla et al. (2015) reported that average height and width were 1.62 ± 0.77 mm and 1.15 ± 0.39 mm, respectively. *Su et al. (1982)* also reported that the mean width of the RW to be 1.66 mm (range 0.48–2.7 mm), on as much as 463 specimens, which are slightly close to our results. Possible reasons for that slight difference were fewer specimens in our study, or a racial or population variability. In another study conducted by *Takahashi et al. (1989)*, they found the maximal diameter to be 2.32 mm. *Erixon et al. (2009)* in their study had reported that the maximal radius of the round window (half diameter of RW) was estimated to be 1.1 mm, with a range from 0.3 to 1.6 mm. The reason for these differences may be difficulties in assessing the reference points because of the RW distorted architecture. We found it is difficult sometimes to define a plane for correct measurements because of the bulging and irregular outline of the RW.

Table 3. Size of Round Window as Reported by Previous and Current Studies.

Authors (year)	Study	No. of specimens	Parameter	Mean	6 SD
Singla et al., 2014	Gross cadaveric	50	RWh	1.62	± 0.77 (0.8–3.77mm)
			RWw	1.15	± 0.39 (0.64–2.15 mm)
Erixon et al., (2009)	Silicon casts	65	Half diameter of RW	1.1 mm	(0.3–1.6 mm)
Cohen et al., (2005)	CT scans of patients	414	RW length	1.665	± 0.258 (1–2.70 mm)
Takahashi et al., (1989)	Cadaveric study (computer-aided 3D reconstruction)	5	Maximum diameter of RW	2.98	± 0.23

Su et al., (1982)	Histological	541	RWw	1.66 mm (0.48–2.7mm)
Current study(2016)	Gross cadaveric	20	RWh	1.91 ± 0.78 mm
Current study(2016)	Gross cadaveric	20	RWw	1.37 ± 0.43

RWh, maximum height of round window; RWw, maximum width of round window.

In this current study, it is important to note that RW height and width were <1 mm in 10% and 25% of the cases, respectively (Fig. 3). These sizes do not allow all the products available in the market to be used (Table 4). An extremely narrow RW makes it difficult to insert an electrode so drilling of the anteroinferior margin may be required. Drilling provides increased visibility and easy access to the RW, thereby allowing the angle of electrode entry to be adjusted for successful insertion into the scala tympani. Drilling the RW margin is not only potentially hazardous because of its close proximity to the cochlear aqueduct opening, but inherent trauma to the cochlea may also result, which can lead to loss of residual hearing in hearing-preservation cases (*Roland et al., 2007*).

Table 4. Dimensions of the currently used electrode arrays ²⁸.

Manufacturers	Electrode	Diameter at apical end (mm)	Diameter at basal end (mm)
Cochlear Corporation	Freedom contour Advance	0.5	0.8
Cochlear Corporation	Freedom Straight	0.4	0.6
Cochlear Corporation	Nucleus Hybrid	0.2	0.4
MED-EL	PULSAR CI ¹⁰⁰	0.5	1.3
Advanced Bionics	HiFocus 1J	0.4	0.8
Advanced Bionics	HiFocus helix	0.6	1.1

From this morphologic investigation, it is possible to conclude that the alternate anatomic features of the human RW may influence its surgical access. In this regard, this study may also help to shape or optimally design future implants aimed at targeting this region.

Relationship of round window to oval window

The oval window forms a direct superior relation to the round window, being separated from the latter by the basal end of the cochlea. In our study, the RW was at an average distance of 2.09 ± 0.69 mm (range 1 – 3.5 mm) from the OW. *Singla et al. (2015)* reported that the minimal distance between RW and oval window was 2.19 ± 0.43 (range 1.39–3.57) in their study on 50 cadaveric temporal bones. This distance was reported to be 1.43 ± 0.279 mm (1–1.75 mm) in a further study conducted on 10 cadaveric temporal bones by *Paprocki et al. (2004)*. In a third study conducted by *Stewart & Belal (1981)*, the distance from the superior margin of the round window niche to the inferior edge of the oval window was found to have a mean value of 2.7 mm, (range 1.9-3.3) in 12 temporal bones. *Dahm et al. (2009)* in another study on 60 cadaver specimens of all ages reported that the mean distance between the round and oval windows, measured from the anterior rim of the stapes footplate to the anteroinferior part of the RW orifice, was found to be 4.1-4.5 mm with an average standard deviation of just 0.34 mm. Possible reasons for these different results were the use of different numbers of specimens, or the racial or population variability and differences in assessing the reference points for measurement in each study.

The most frequent error is inadvertent implantation of a hypotympanic air cell, which is more likely to occur if the round window niche is not clearly identified. This may occur even in experienced hands if there is fibrous or bony obliteration of the niche. Therefore, reliance on other landmarks (i.e. oval window position) after opening the facial recess is important. The surgeon must be able to identify the round window niche and promontory, and not be misled by hypotympanic air cells³¹.

A knowledge of the RW-OW distance is also significant for the surgeons who are performing stapedectomy because of the risk of unintended injury to the RW membrane or of opening the vestibule. *Atturo et al. (2014)* reported that in ears with a large distance between the

OW and RW, nontraumatic cochleostomy drilling was more often achieved than at a small distance.

CONCLUSION

Prior information about possible anatomical variations of the RW and its relationships to the OW is expected to reduce complications in CI surgery and in the emerging field of drug delivery to the inner ear. The presence or absence of these anatomical variations might not always be understood during a preoperative CT study, and a knowledge of them could help to modify the criteria adopted for management by an otological surgeon.

Limitation of the Study

Fewer temporal bones were available especially from the lower age group (<18 years). Further studies on this age group could validate our results.

Recommendations

We found it difficult sometimes to define a plane for correct measurements because of the bulging and irregular outline of the RW region. Therefore, 3-D reconstruction studies from stereo-cameras should be performed as a next step. Such a study could also give a better comprehension of the complex 3-D shape and geometry of the RW region anatomy.

ACKNOWLEDGMENTS

The authors sincerely thank Dr Sherif El-Taher for his help in data analysis.

REFERENCES

1. Adunka O, Gstoettner W, Hambek M, Unkelbach MH, Radloff A,

- Kiefer J. Preservation of basal inner ear structures in cochlear implantation. *Orl*. 2004;66(6):306-312. doi:10.1159/000081887.
2. Roland PS, Wright CG, Isaacson B. Cochlear implant electrode insertion: the round window revisited. *Laryngoscope*. 2007;117(8):1397-1402. doi:10.1097/MLG.0b013e318064e891.
 3. Skarzynski H, Lorens A, Piotrowska A, Anderson I. Partial deafness cochlear implantation provides benefit to a new population of individuals with hearing loss. *Acta Otolaryngol*. 2006;126(9):934-940. doi:10.1080/00016480600606632.
 4. Gstoettner W, Helbig S, Settevendemie C, Baumann U, Wagenblast J, Arnoldner C. A new electrode for residual hearing preservation in cochlear implantation: first clinical results. *Acta Otolaryngol*. 2009;129(4):372-379. doi:10.1080/00016480802552568.
 5. Meshik X, Holden T a, Chole R a, Hullar TE. Optimal cochlear implant insertion vectors. *Otol Neurotol*. 2010;31(1):58-63. doi:10.1097/MAO.0b013e3181b76bb8.
 6. Pau HW, Just T, Bornitz M, Lasurashvilli N, Zahnert T. Noise Exposure of the Inner Ear During Drilling a Cochleostomy for Cochlear Implantation. *Laryngoscope*. 2007;117(3):535-540. doi:10.1097/MLG.0b013e31802f4169.
 7. Cipolla MJ, Iyer P, Dome C, Welling DB, Bush ML. Modification and comparison of minimally invasive cochleostomy techniques: A pilot study. *Laryngoscope*. 2012;122(5):1142-1147. doi:10.1002/lary.23231.
 8. Roland JT. A Model for Cochlear Implant Electrode Insertion and Force Evaluation: Results with a New Electrode Design and Insertion Technique. *Laryngoscope*. 2005;115(8):1325-1339. doi:10.1097/01.mlg.0000167993.05007.35.
 9. Nadol JB, Eddington DK. Histologic evaluation of the tissue seal and biologic response around cochlear implant electrodes in the human. *Otol Neurotol*. 2004;25(3):257-262.
 10. TODT I, BASTA D, ERNST A. Does the surgical approach in cochlear implantation influence the occurrence of postoperative vertigo? *Otolaryngol - Head Neck Surg*. 2008;138(1):8-12. doi:10.1016/j.otohns.2007.09.003.
 11. Paprocki A, Biskup B, Kozłowska K, Kuniszyk A, Bien D, Niemczyk K. The topographical anatomy of the round window and related structures for the purpose of cochlear implant surgery. *Folia Morphol (Warsz)*. 2004;63(3):309-312.
 12. Ying Y-LM, Lin JW, Oghalai JS, Williamson RA. Cochlear implant electrode misplacement: Incidence, evaluation, and management. *Laryngoscope*. 2013;123(3):757-766. doi:10.1002/lary.23665.
 13. Singla A, Sahni D, Gupta AK, Aggarwal A, Gupta T. Surgical

- Anatomy of Round Window and Its Implications for Cochlear Implantation. *Otol Neurotol*. 2015;36(2):323-328. doi:10.1097/MAO.0000000000000371.
14. Cohen NL, Hoffman RA. Complications of Cochlear Implant Surgery in Adults and Children. *Ann Otol Rhinol Laryngol*. 1991;100(9):708-711. doi:10.1177/000348949110000903.
 15. Jain R, Mukherji S. Cochlear Implant Failure: Imaging Evaluation of the Electrode Course. *Clin Radiol*. 2003;58(4):288-293. doi:10.1016/S0009-9260(02)00523-8.
 16. Plontke SKR, Plinkert PK, Plinkert B, Koitschev A, Zenner H-P, Löwenheim H. Transtympanic endoscopy for drug delivery to the inner ear using a new microendoscope. *Adv Otorhinolaryngol*. 2002;59:149-155.
 17. Hoffman RA, Cohen NL. Complications of cochlear implant surgery. *Ann Otol Rhinol Laryngol Suppl*. 1995;166:420-422.
 18. Dowell RC, Hollow R, Winton E. Outcomes for Cochlear Implant Users With Significant Residual Hearing. *Arch Otolaryngol Neck Surg*. 2004;130(5):575. doi:10.1001/archotol.130.5.575.
 19. Adunka O, Kiefer J, Unkelbach MH, Lehnert T, Gstoettner W. Development and Evaluation of an Improved Cochlear Implant Electrode Design for Electric Acoustic Stimulation. *Laryngoscope*. 2004;114(7):1237-1241. doi:10.1097/00005537-200407000-00018.
 20. Gantz BJ, Turner C, Gfeller KE, Lowder MW. Preservation of hearing in cochlear implant surgery: advantages of combined electrical and acoustical speech processing. *Laryngoscope*. 2005;115(5):796-802. doi:10.1097/01.MLG.0000157695.07536.D2.
 21. Gstoettner W, Kiefer J, Baumgartner W-D, Pok S, Peters S, Adunka O. Hearing preservation in cochlear implantation for electric acoustic stimulation. *Acta Otolaryngol*. 2004;124(4):348-352. doi:10.1080/00016480410016432.
 22. Atturo F, Barbara M, Rask-Andersen H. Is the human round window really round? An anatomic study with surgical implications. *Otol Neurotol*. 2014;35(8):1354-1360. doi:10.1097/MAO.0000000000000332.
 23. Bonaldi L, De Angelis MA, Smith RL. Developmental Study of the Round Window Region. *Cells Tissues Organs*. 1997;159(1):25-29. doi:10.1159/000147961.
 24. Takahashi H, Sando I, Takagi A. Computer-Aided Three-Dimensional Reconstruction and Measurement of the Round Window Niche. *Laryngoscope*. 1989;99(5):505-509. doi:10.1288/00005537-198905000-00008.
 25. Erixon E, Högstorp H, Wadin K, Rask-Andersen H. Variational Anatomy of the Human Cochlea. *Otol Neurotol*. 2009;30(1):14-22.

- doi:10.1097/MAO.0b013e31818a08e8.
26. Su W-Y, Marion MS, Matz GJ, Hinojosa R. Anatomical Measurements Of The Cochlear Aqueduct, Round Window Membrane, Round Window Niche, And Facial Recess. *Laryngoscope*. 1982;92(5):483–486. doi:10.1288/00005537-198205000-00003.
 27. Cohen D, Blinder G, Perez R, Raveh D. Standardized computed tomographic imaging and dimensions of the round-window niche. *Int Tinnitus J*. 2005;11(2):158-162.
 28. Li PMMC, Wang H, Northrop C, Merchant SN, Nadol JB. Anatomy of the round window and hook region of the cochlea with implications for cochlear implantation and other endocochlear surgical procedures. *Otol Neurotol*. 2007;28(5):641-648. doi:10.1097/mao.0b013e3180577949.
 29. Stewart TJ, Belal A. Surgical anatomy and pathology of the round window. *Clin Otolaryngol Allied Sci*. 1981;6(1):45-62.
 30. Dahm MC, Shepherd RK, Clark GM. The Postnatal Growth of the Temporal Bone and its Implications for Cochlear Implantation in Children. *Acta Otolaryngol*. 2009;113(March):4-39. doi:10.3109/00016489309128539.
 31. Buchman CA, Higgins CA, Cullen R, Pillsbury HC. Revision cochlear implant surgery in adult patients with suspected device malfunction. *Otol Neurotol*. 2004;25(4):504-10; discussion 510.
 32. Atturo F, Barbara M, Rask-Andersen H. On the anatomy of the “hook” region of the human cochlea and how it relates to cochlear implantation. *Audiol Neurotol*. 2014;19(6):378-385. doi:10.1159/000365585.